

Hemostasis and thrombosis in patients with liver disease: The ups and downs

Ton Lisman^{1,2,*}, Stephen H. Caldwell³, Andrew K. Burroughs⁴, Patrick G. Northup³, Marco Senzolo⁵, R. Todd Stravitz⁶, Armando Tripodi⁷, James F. Trotter⁸, Dominique-Charles Valla⁹, Robert J. Porte¹,
Coagulation in Liver Disease Study Group

¹Section Hepatobiliary Surgery and Liver Transplantation, The Netherlands; ²Surgical Research Laboratory, Department of Surgery, University Medical Center Groningen, University of Groningen, Groningen, The Netherlands; ³Division of GI/Hepatology, Department of Internal Medicine, University of Virginia, Charlottesville, VA, USA; ⁴The Sheila Sherlock Hepatobiliary-Pancreatic and Liver Unit, Royal Free Hospital, London, United Kingdom; ⁵Gastroenterology, Department of Surgical and Gastroenterological Sciences, University Hospital of Padua, Italy; ⁶Section of Hepatology, Hume-Lee Transplant Center, Virginia Commonwealth University, Richmond, VA, USA; ⁷Angelo Bianchi Bonomi Hemophilia and Thrombosis Center, University Medical School and IRCCS Ospedale Maggiore Policlinico, Mangiagalli and Regina Elena Foundation, Milan, Italy; ⁸Baylor University Medical Center, Dallas, TX, USA; ⁹Centre de Référence des Maladies Vasculaires du Foie, AP-HP, Hôpital Beaujon, Service d'Hépatologie, Clichy, France

Abstract

Patients with chronic or acute liver failure frequently show profound abnormalities in their hemostatic system. Whereas routine laboratory tests of hemostasis suggest these hemostatic alterations result in a bleeding diathesis, accumulating evidence from both clinical and laboratory studies suggest that the situation is more complex. The average patient with liver failure may be in hemostatic balance despite prolonged routine coagulation tests, since both pro- and antihemostatic factors are affected, the latter of which are not well reflected in routine coagulation testing. However, this balance may easily tip towards a hypo- or hypercoagulable situation. Indeed, patients with liver disease may encounter both hemostasis-related bleeding episodes as well as thrombotic events. During the 3rd International Symposium on Coagulopathy and Liver disease, held in Groningen, The Netherlands (18–19 September 2009), a multidisciplinary panel of experts critically reviewed the current data concerning pathophysiology and clinical consequences of hemostatic disorders in patients with liver disease. Highlights of this symposium are summarized in this review.

Introduction

In patients with liver disease, substantial changes in the hemostatic system are frequently found [1]. These changes include thrombocytopenia and platelet function defects, decreased circulating levels of coagulation factors and inhibitors, and decreased levels of proteins involved in fibrinolysis. Consequently, routine diagnostic tests of hemostasis, such as the platelet count, the prothrombin time (PT), and the activated partial thromboplastin time (APTT) are frequently abnormal. In patients with isolated hemostatic defects, such abnormalities in these laboratory tests often indicate a true bleeding tendency. However, interpretation of these tests is much less straightforward in the patient with a complex hemostatic disorder as can be found in patients with liver disease. In recent years, traditional concepts on the clinical consequences of the hemostatic disorder in patients with liver disease have dramatically changed. In particular, it is now established that patients with liver disease and abnormal routine coagulation tests do not necessarily have an increased bleeding tendency [2,3], and that even thrombotic complications may occur in these patients [4]. During the 3rd International Symposium on Coagulopathy and Liver disease, held in Groningen, The Netherlands (18–19 September 2009), a multidisciplinary panel of experts critically reviewed the current data concerning pathophysiology and clinical consequences of hemostatic disorders in patients with liver disease. Highlights of this symposium will be summarized in this review.

Keywords: Liver disease; Hemostasis; Thrombosis; Bleeding; Thrombin; Platelet; Non-alcoholic steatohepatitis.

Received 11 January 2010; received in revised form 28 January 2010; accepted 29 January 2010

* Corresponding author. Address: Surgical Research Laboratory, BA 44, University Medical Center Groningen, Hanzplein 1, 9713GZ Groningen, The Netherlands. Tel.: +31 50 3619028; fax: +31 50 363 2796.

E-mail address: j.a.lisman@chir.umcg.nl (T. Lisman).

Abbreviations: PT, prothrombin time; APTT, activated partial thromboplastin time; VWF, von Willebrand factor; NAFLD, non-alcoholic fatty liver disease; PAI-1, plasminogen activator inhibitor-1; NASH, non-alcoholic steatohepatitis; INR, international normalized ratio; EVL, endoscopic variceal ligation; ALF, acute liver failure; rFVIIa, recombinant factor VIIa; ICP, intracranial pressure; PVT, portal vein thrombosis; HAT, hepatic artery thrombosis; AASLD, American society for the study of liver diseases.

Hemostatic abnormalities in liver disease: the concept of rebalanced hemostasis

Chronic liver disease – rebalanced hemostasis?

Thrombocytopenia, platelet function defects, and decreased levels of pro- and anticoagulant proteins are frequently observed in patients with cirrhosis [5]. Although routine hemostatic tests



such as the platelet count and the PT/APTT may indicate a bleeding tendency, clinical and laboratory evidence indicate that the hemostatic system is in a 'rebalanced' status, since changes in prohemostatic pathways are accompanied by changes in antihemostatic pathways [3,5,6] (summarized in Table 1).

For example, the defects in platelet number and function are, at least in part, compensated for by highly elevated levels of the platelet adhesive protein von Willebrand factor (VWF), and by decreased levels of the von Willebrand factor cleaving protease ADAMTS13 [7,8]. The result is enhanced platelet adherence evident in *in vitro* testing. Endothelial changes, which have been very little explored, may also be important. For example, a decreased thromboprotective glycocalyx on endothelial cells, which is affected in many disease states including inflammatory states and atherosclerosis [9] could promote platelet adhesion and aggregation. Indeed, increased plasma levels of glycosaminoglycans are present in patients with liver disease, which could be a reflection of endothelial glycocalyx breakdown [10].

Furthermore, decreased levels of procoagulant proteins are accompanied by decreased levels of natural anticoagulant proteins [11,12]. In addition, routine laboratory tests such as the PT and APTT are insensitive for plasma levels of anticoagulant proteins whereas more sophisticated laboratory tests have indicated an intact thrombin generating capacity in patients with cirrhosis [11]. In particular, patients with liver disease are resistant to the action of thrombomodulin, the physiological activator of the anticoagulant protein C [12,13]. Finally, reduced levels of inhibitors of fibrinolysis are, at least in part, balanced by reduced levels of profibrinolytic factors, in particular plasminogen [14]. The net effect of all hemostatic changes thus is often a rebalanced, yet functional system. However, the balance is far more precarious and potentially unstable compared to the hemostatic balance in healthy individuals, which explains the potential occurrence of both bleeding and thrombotic complications in patients with cirrhosis (Fig. 1).

The special case of non-alcoholic fatty liver disease

Non-alcoholic fatty liver disease (NAFLD) represents the hepatic manifestation of the metabolic syndrome. As such, afflicted patients suffer an increased burden of both thrombotic vascular disease and progressive liver disease [15]. Patients with NAFLD may initially present with hemostatic alterations linked to gen-

eral metabolic imbalance including high levels of plasminogen activator inhibitor-1 (PAI-1; now considered a component of the metabolic syndrome), increased levels of VWF, factor VII, soluble tissue factor and fibrinogen, as well as platelet hyperaggregability and endothelial dysfunction [16–20]. Thus NAFLD is clearly associated with a prothrombotic state, which is reflected in a substantially increased incidence of thrombotic events in patients with NAFLD (see below). It remains to be established whether progression to cirrhosis is associated with concomitant changes in the hemostatic status but it is likely that patients with advanced cirrhosis as a result of NAFLD or non-alcoholic steatohepatitis (NASH) have a (rebalanced) hemostatic status comparable to the cirrhosis patient with a viral or alcoholic etiology.

Acute liver failure

The coagulopathy of patients with acute liver failure is relatively less studied but changes are similar to those observed in cirrhosis with a number of notable exceptions [21]. For example, thrombocytopenia is less common in patients with acute liver failure. On the other hand, the reduction in circulating pro- and anticoagulant proteins is more severe as compared with patients with cirrhosis [22], and fibrinolysis is shifted toward a hypofibrinolytic state as a result of substantially increased plasma levels of PAI-1 [23]. Although laboratory values of coagulation are without exception abnormal in the patient with acute liver failure (elevated international normalized ratio (INR) is one of the diagnostic criteria), the concept of rebalanced hemostasis seems to apply to these patients as well since in general there is no predictable and consistent bleeding risk (see below).

Bleeding complications in patients with liver disease

Bleeding is common in liver disease (Table 2). However, recent research casts doubt on its relation to conventional coagulation indices and our ability to measure the risk. [3,24–29].

Chronic liver disease

The most frequent bleeding complication in patients with cirrhosis, variceal bleeding, is at least in part, unrelated to hemostasis and depends more on local vascular abnormalities and portal hypertension leading to increased vascular pressure [46]. On the other hand, some studies have shown that patients with bleeding varices have more pronounced abnormalities in the hemostatic system than patients that do not bleed [47–49]. The existence of the platelet plug or 'nipple' sign as a marker of variceal bleeding site also suggests some limited role of hemostasis. However, intravascular volume and portal hypertension is usually the dominant factor in the pathogenesis of variceal bleeding [50]. This has led to the general recommendation for a very conservative volume resuscitation in this setting [30,51–53].

The important relationship between maintenance of low volume and hemostasis in cirrhosis is exemplified by the observation that, with careful volume control, a substantial proportion of patients with endstage liver disease can undergo a liver transplantation without the requirement for any blood transfusion [27–29]. The routine use of prophylactic transfusion of blood products in cirrhotic patients undergoing an invasive procedure is thus questionable, especially in view of the substantial side effects that are accompanied by blood product transfusion, including fluid overload and exacerbation of portal hypertension,

Table 1. Alterations in the hemostatic system in patients with liver disease that contribute to bleeding (left) or counteract bleeding (right).

Changes that impair hemostasis	Changes that promote hemostasis
Thrombocytopenia	Elevated levels of von Willebrand factor (VWF)
Platelet function defects	Decreased levels of ADAMTS-13
Enhanced production of nitric oxide and prostacyclin	Elevated levels of factor VIII
Low levels of factors II, V, VII, IX, X, and XI	Decreased levels of protein C, protein S, antithrombin, α 2-macroglobulin, and heparin cofactor II
Vitamin K deficiency	
Dysfibrinogenemia	Low levels of plasminogen
Low levels of α 2-antiplasmin, factor XIII, and TAFI	
Elevated t-PA levels	

Source: Modified from the European Association for the Study of the Liver from Lisman et al. [1] with permission.

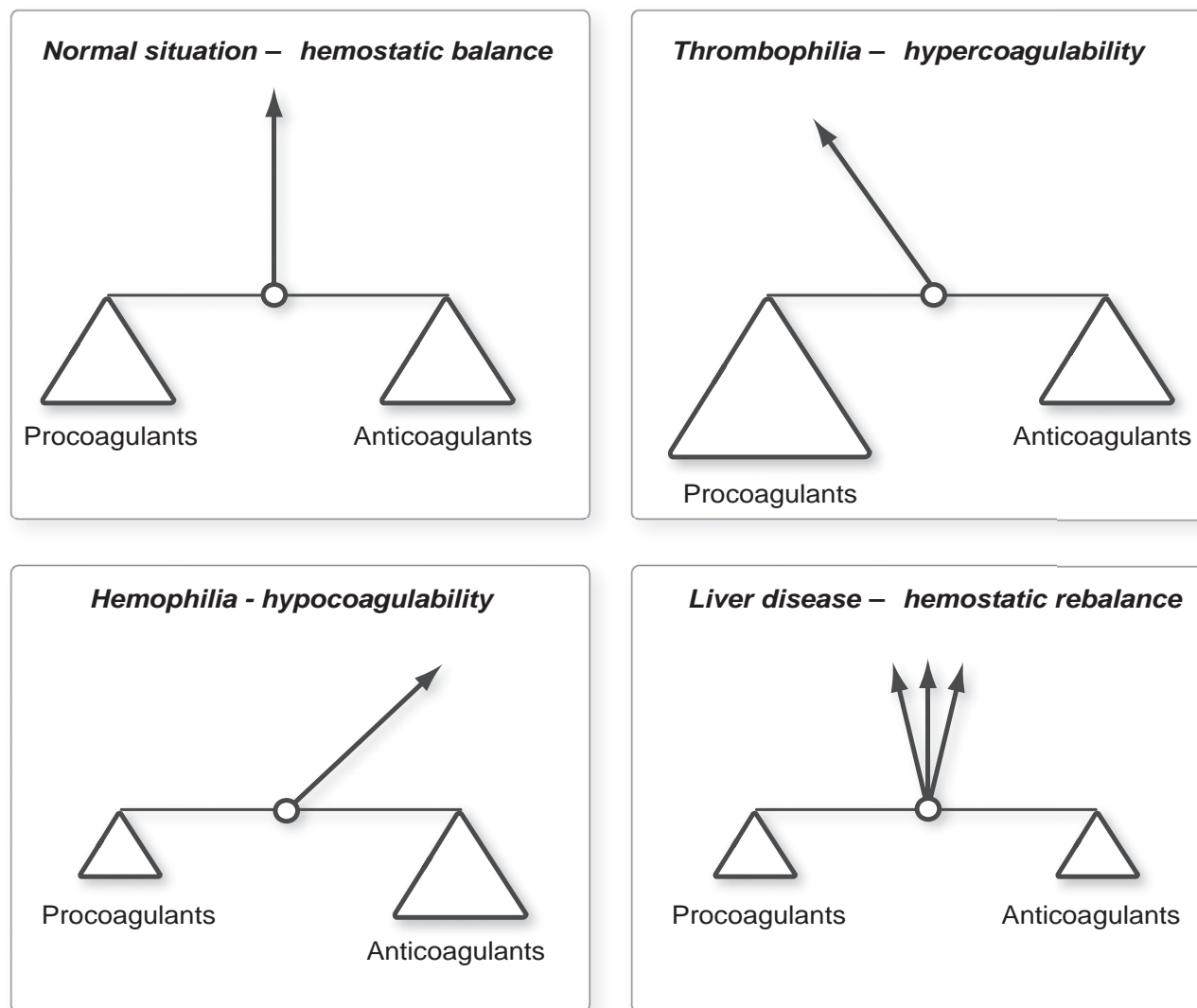


Fig. 1. In healthy individuals, hemostasis is a well balanced system of pro- and anticoagulant factors. In thrombophilic situations, e.g., in carriers of factor V Leiden, the hemostatic balance is shifted towards a hypercoagulable status, whereas in hemophilia and allied disorders, the hemostatic balance is shifted towards a bleeding tendency. In patients with liver disease, in whom both pro- and anticoagulant proteins are present in reduced levels, a rebalanced hemostatic state is present. However, the balance is much more precarious as compared to the balance in healthy individuals, and may easily shift to either hypo- or hypercoagulability.

risk of infection, and risk of transfusion-related acute lung injury [54–57]. Indeed, this has shifted clinical emphasis away from prophylaxis and towards rescue therapy in many interventional settings [58].

Acute liver failure

The bleeding risk in patients with acute liver failure (ALF) was traditionally estimated to be higher than that of cirrhosis, which may be related to the increased severity of hemostatic alterations. However, there has been an unexplained decline in severe bleeding reported in patients with ALF over the past 40 years. Bleeding was a cause of death in about one third of patients with ALF in the 1970's whereas currently bleeding is an uncommon cause of death in these patients [21]. Furthermore, spontaneous and clinically significant bleeding is rare in current experience. Routine prophylactic correction of coagulation is currently

discouraged in ALF [45] because of the uncertain benefit and the potential harm of volume expansion with plasma which may worsen intracranial hypertension [59] or products such as recombinant factor VIIa (rFVIIa) which carry thrombotic risks. The risk of potentially fatal intracranial bleeding with placement of an ICP monitor, varies with the depth of the monitor device, but ranges from 3% to 10%, as shown by prospectively collected data from the Acute Liver Failure Study Group from the United States [60]. In this setting, ALF guidelines recommend cautious use of prophylactic rFVIIa although this is by expert opinion rather than evidence based.

The role of bacterial infection: antibiotic prophylaxis to prevent bleeding?

In liver disease, minor disturbances may tip the balance in these patients to either bleeding or thrombosis. One of the

Table 2. Potential bleeding problem/sites in liver disease.

Condition	Comment	Intervention and caveats
Variceal bleeding	More pressure driven but platelet plug sign suggests possible role of hemostatic system in re-bleeding risk	Primarily endoscopic or antiportal hypertension medication. Role of procoagulants not established. Avoid marked volume expansion [30]
Variceal Prophylactic Band Ligation (EVL)	Poor relationship of post-EVL bleeding and expanded indices of coagulation [31]	No specific intervention. Increased risk in Child-Pugh C suggests therapy aimed at portal hypertension
Portal hypertensive gastropathy	Primarily mechanical as suggested by response to TIPS or beta-blockade [32]	Portal decompression either mechanical or pharmacological
Gastric vascular ectasia	Microvascular disorder. Relationship to hemostatic defects is not well-explored [33]	Sometimes refractory. No definitive therapy but often treated with endoscopic cauterization
Vascular access sites	Common issue for a variety of interventions. Specific INR cutoffs should probably be abandoned due to limitations of the test	Limit volume expansion. Optimize platelets
Cardiac Catheterization	Higher incidence of pseudoaneurysms and higher transfusion needs [34]	Optimal preventive strategies remain to be defined. The increased risk of pseudoaneurysms suggests primary vascular problem
Paracentesis	Extensive data exists to support the absence of predictable bleeding based on common indices of coagulation [35]	No prophylactic measures in average risk patients
Thoracentesis	Often necessary for hepatic hydrothorax. Very little published data but a few series suggest relative safety	Chest wall collaterals pose a hazard. Limit volume expansion to avoid engorgement. Optimize platelets
Percutaneous Liver Biopsy	Major bleeding is not well-predicted by conventional coagulation indices. Hyperfibrinolysis can result in delayed massive bleeding [36]	Definitive cutoffs not established but optimization of platelets is recommended
Transvenous Liver Biopsy	Often utilized with higher perceived risk, with ascites or when pressure measures are needed	Transcapsular bleeding risk present with about the same frequency as percutaneous biopsy but in a higher risk population
Generalized Mucosal Bleeding	Generalized bleeding from mucosal surfaces especially gums or gastrointestinal tract	May indicate the presence of fibrinolytic disorder [37]
Colonoscopic Polypectomy	Colonoscopic screening is common pre-transplant Incidence of polyps may be increased but risk of bleeding with resection is uncertain [38]	Larger, potentially vascular polyps probably pose an increased hazard. Prophylactic versus rescue strategies not well studied
ERCP and SO Sphincterotomy	Cholelithiasis increased in cirrhosis. Risk of significant bleeding with conventional sphincterotomy is about 15%	Bleeding in this setting may be more related to portal hypertension warranting emphasis on preventive strategies to address this aspect [39]
Contusions, Cutaneous Hematomas	While sometimes dismissed as 'cosmetic', these can lead to compartment syndromes and represent significant blood loss	The development of severe hematomas suggests the presence of a net bleeding diathesis and warrants careful investigation
ERCP and SO Tooth extractions	Frequently performed with delayed bleeding in a significant proportion of patients	High fibrinolytic activity in oral cavity suggests a role for antifibrinolytics in this setting: topical versus systemic [40]
Post-operative wound bleeding	Major surgery (such as orthopedic) may be associated with intractable wound bleeding	Mechanisms remain uncertain but endothelial dysfunction and fibrinolytic mechanisms seem likely
Tracheostomy	In decompensated cirrhosis, tracheostomy may be necessary. Bleeding risk does not appear to be prohibitive	Blood product use is predicted by pre-op conventional indices but it is unclear if correction is beneficial [41]
Extracorporeal Perfusion Circuits	Patients are increasingly exposed to dialysis circuits and artificial liver support devices. Prophylaxis for circuit thrombosis may be complicated by bleeding [42]	Management is complex but includes citration and re-calcification of the blood passing through the circuits [43]
Intracranial bleeding, Subdural hematoma	May present as encephalopathy. Suspicion should increase with recent trauma (even minor), focal deficit or failure to improve with conventional therapy of PSE	Risk in cirrhosis is controversial but appears to be increased in both ethanol-related and other forms of cirrhosis [44]
ICP Monitor in ALF	Risk of bleeding varies significantly with device (epidural, subdural parenchymal) but accuracy similarly varies [21]	Because of the severity of outcome with bleeding, prophylactic rFVIIa is often recommended [45]

ERCP, endoscopic retrograde cholangiopancreatography, SO, sphincter of Oddi, ICP, intracranial pressure.

superimposed conditions is bacterial infection which is common in these patients [61], associated with increased mortality and with gastrointestinal bleeding [62,63]. Up to two-thirds of patients with gastrointestinal bleeding have a bacterial infection. Moreover, thromboelastographic studies have shown a hypocoagulable state in cirrhotic patients with an active infection, and this has been associated with an increased bleeding risk [64]. Increased circulating heparin-like molecules are in part responsible for this hypocoagulable state [65,66]. Prophylactic administration of antibiotics has been shown to reduce both mortality and bleeding risk. Whether this results primarily from improved hemodynamics or improved hemostasis or both is uncertain, and is an important area to distinguish the pathoetiological factors of investigation [67–69].

Thrombosis in chronic liver disease

Venous and arterial thrombosis

For decades, the paradigm has prevailed that patients with cirrhosis are 'autoanticoagulated' (as evidenced by a prolonged PT and APTT) and thus protected from thrombotic episodes such as deep venous thrombosis and pulmonary embolism. However, recent studies have indicated that venous thrombosis does occur in patients with cirrhosis, even in those patients that receive thromboprophylactic measures including pharmacological thromboprophylaxis [70–73]. A population-based study in Denmark reported that liver disease is even associated with an increased risk of venous thrombosis compared to individuals without liver disease [71]. Similarly, cirrhotic patients are not

Meeting report

'auto-protected' from pulmonary embolism during liver transplantation even when conventional coagulation tests are markedly prolonged [74].

On the other hand, the incidence of arterial thrombosis, including coronary artery disease and ischemic stroke, was traditionally thought to be lower in cirrhosis compared to the general population [75–77]. However, population based studies that adjust for age and alcohol consumption (which is generally thought to be moderately protective against coronary artery disease) have questioned this traditional concept [78,79]. A well established exception is NASH-related cirrhosis where the incidence of arterial thrombosis is increased (see below). A similar finding in patients with alcoholic liver disease was also recently reported [80].

Portal vein thrombosis

Patients with cirrhosis frequently develop portal vein thrombosis (PVT) during the course of their disease (reviewed in [81]). Approximately 15% of patients will have an overt PVT at the time of liver transplantation, and the incidence of occult PVT is even higher [82,83]. Patients with PVT and cirrhosis have a more severe clinical course than those without. PVT is associated with (and might cause) aggravated portal hypertensive bleeding, ascites, encephalopathy, hyperdynamic circulation, and may lead to intestinal ischemia [84–86]. Risk factors for PVT include the prothrombin 20210A mutation and decreased portal flow [83,86]. PVT may recur following liver transplantation and, depending on the location of the thrombus, PVT may adversely affect survival after transplantation [82,87]. These problems have led to reports of more aggressive management of these patients (see below).

Hepatic artery thrombosis (HAT) after liver transplantation

Thrombosis of the hepatic artery may occur both early and late after liver transplantation. Early HAT frequently occurs when routine laboratory values have not completely normalized and thus paradoxically indicate a hypocoagulable state. Although mechanical factors are often involved, increasing evidence indicates that postoperative hypercoagulability is a contributing factor as well [88]. Indeed, more sophisticated tests such as calibrated automated thrombinography indicate a hypercoagulable state, which may be linked to the risk of HAT [13]. Interestingly, preoperative PVT was recently identified as a strong predictor of a postoperative HAT, which may indicate that a general (relative) hypercoagulable state may be involved in the pathogenesis of HAT (Northup et al., unpublished data).

Thrombosis as a contributor of progression of fibrosis

Both in animal models and in human explants, microthrombi in the liver vasculature can be observed in fibrotic areas [89,90]. These observations have led to the hypothesis that coagulation activation within the liver vasculature occurs in response to the fibrotic process and contribute to progression of fibrosis by inducing local ischemia (a process known as 'parenchymal extinction') [89]. In addition, activation of stellate cells by coagulation proteases such as thrombin and factor Xa may play a role [91–93]. Indeed, both epidemiological and experimental data have shown that carriage of factor V Leiden leads to an acceler-

ated progression of fibrosis [94,95]. Conversely, treatment with anticoagulant drugs attenuates progression of fibrosis in animal models [94,96]. The effect of warfarin anticoagulation on fibrosis progression in patients with post-transplant hepatitis C is currently being examined in an ongoing clinical study in the United Kingdom (ClinicalTrials.gov identifier: NCT00180674).

Thrombotic complications in patients with NAFLD

Patients with NAFLD are not only at severely increased risk for death from liver-related causes, as compared to a healthy population, but also show an increased prevalence of cardiovascular disease which constitutes the leading cause of death in this group [15]. This is clearly related due to overlapping risk factors such as dyslipidemia, diabetes, hypertension, and the metabolic syndrome. Obesity, a major risk factor for NAFLD, is associated with impaired fibrinolysis, resistance to antiplatelet agents, and platelet hyperreactivity [16,17,97]. Moreover, steatosis has been associated with enhanced PAI-1 and factor VII activity [17]. In addition, altered clot kinetics have recently been described in non-cirrhotic patients with NAFLD and the presence of thrombotic risks has been correlated with the degree of fibrosis in patients with NASH [98,99]. In the setting of these converging risks, we can foresee increasing numbers of patients with both liver disease and cardiovascular diseases. Management of related issues such as the response to antiplatelet agents in these patients will confront clinicians with new challenges.

Management of bleeding and bleeding risk

Despite a substantial increase in data on the pathological changes in coagulation in patients with liver disease, little clinical data is available to guide management of bleeding. Management of bleeding complications or prophylactic administration of blood products or prohemostatic drugs varies widely between different centers and no general guidelines for patients with liver disease are available.

An area in which data have become available is the prophylactic management of patients during liver transplantation. It has been clearly demonstrated that a restrictive transfusion policy during liver transplantation is feasible, and results in a substantial proportion of patients that are transplanted without any requirement for blood products [29,100]. Based on these data, and on the increasing awareness of the detrimental side effects of blood transfusion, a revision of the prophylactic transfusion strategy during other procedures seems justified. In some centers a wait-and-see (rescue) policy is used in which blood products are only administered when active bleeding occurs in contrast to a prophylactic transfusion strategy. This approach is supported by the uncertainty surrounding laboratory targets of prophylactic therapy. While there is recent data to indicate sufficient thrombin production with platelet levels exceeding 50,000 per microliter [101], much less is substantiated for use of fresh frozen plasma. Arguments in favor of the wait-and-see transfusion policy include the notion that the efficacy of prophylactic infusions has not been demonstrated [33]. In fact, complete normalization of laboratory parameters in cirrhotic patients is rarely achieved by administration of platelet concentrates or fresh frozen plasma [102]. Furthermore, these products may have detrimental side effects including exacerbation of portal hypertension (which

Table 3. The advantages and disadvantages of various strategies available to prevent or treat bleeding in patients with liver disease.

Product	Pro	Con
Red cell concentrate	Life saving in case of severe anemia, improvement of platelet function	Transfusion-related side effects, adversely affects outcome of liver transplantation
Plasma	Repletes both pro- and anticoagulants	Transfusion-related side effects, fluid overload, exacerbation of portal hypertension. Very commonly under-dosed
Platelet concentrate	Improves primary hemostasis. Recent data showed adequate thrombin production with levels exceeding 50,000 per microliter	Transfusion-related side effects, adversely affects outcome of liver transplantation
Recombinant factor VIIa	Small volume product, encouraging data from uncontrolled studies and case reports	Cost, no proven effect in randomized trials in patients with liver disease, theoretical risk of thrombosis
DDAVP	Laboratory improvement of primary hemostasis, relative lack of side effects, easy administration	Efficacy in patients with liver disease is not proven
Factor concentrates	Small volume product	Only repletes part of the coagulation factors (some products only replete procoagulants), no data from controlled studies yet, theoretical risk of thrombosis
Thrombopoietin receptor agonists	Effectively increases endogenous platelet count, no transfusion-related side effects	No data from controlled studies on efficacy, theoretical risk of thrombosis
Antibiotics	Reduces variceal bleeding, and improves coagulation status in patients with active infection, improvement of systemic hemodynamics	Bacterial resistance or overgrowth

DDAVP, 1-desamino-8-D-arginine vasopressin.

may promote bleeding), transfusion-related acute lung injury (TRALI), as well as several other transfusion reactions [54–57].

Potentially more attractive prohemostatic strategies in patients with cirrhosis are recombinant factor VIIa, prothrombin complex concentrates, antifibrinolytic agents, and desmopressin. Although recombinant factor VIIa is very effective in normalizing a prolonged PT in patients with liver disease [103], randomized controlled trials have failed to show efficacy of this drug in reducing blood loss during liver surgery in patients with cirrhosis [104–106] or in variceal bleeding [107]. Some data even indicate that the product may be thrombogenic [108]. Desmopressin has been shown to improve laboratory parameters of primary hemostasis (including the ex-vivo bleeding time) [109,110], but there is very little evidence for clinical efficacy in patients with liver disease [111–113]. In one study, the addition of desmopressin did not improve and probably worsened the efficacy of terlipressin in controlling acute variceal bleeding in cirrhotic patients [111]. Antifibrinolytic agents such as aprotinin and tranexamic acid have been shown to reduce blood loss during liver transplantation [114,115]. No placebo-controlled studies have yet investigated the efficacy of antifibrinolytic drugs in other procedures or during spontaneous bleeding episodes. Experience with prothrombin complex concentrates in patients with liver disease is also very limited. A major advantage of these products as compared to plasma is the small volume in which the concentrates are administered, thus avoiding the fluid overload and increase in portal hypertension that may be associated with plasma infusion. However, prothrombin complex concentrates have been associated with an increased risk for thrombotic events [116], which should be monitored carefully in future clinical studies.

A novel strategy to improve platelet function in patients with hepatitis C is the administration of a thrombopoietin analog (Eltrombopag) which has been shown to substantially increase the platelet count in these patients [117]. However, since Eltrombopag resulted in hypercorrection of the platelet count in some patients, a theoretical risk of thrombosis occurs, especially in light of the highly elevated VWF levels in these patients [7]. A randomized controlled trial of Eltrombopag in patients with liver disease and thrombocytopenia undergoing invasive procedures has recently been suspended (ClinicalTrials.gov identifier: NCT00678587). The advantages and disadvantages of the various

therapeutic strategies to treat bleeding in patients with liver disease are summarized in Table 3. Clinical studies examining safety and efficacy of the various products for the different bleeding complications need to be initiated.

Management of thrombosis

Venous thrombosis

Since venous thrombotic events are more prevalent than previously assumed, it appears justified to consider thromboprophylactic strategies in these patients especially when hospitalized, immobilized patients or undergoing major surgical procedures [118]. However, little data is available to guide therapy in this group and a cautious approach is warranted. In the past, pharmacological thromboprophylaxis was often withheld in these patients based on the assumed bleeding risk. Indeed, patients with an increased bleeding risk due to bacterial infection or renal failure may not be suitable candidates for pharmacological therapy, but may benefit from mechanical thromboprophylaxis with stockings or pneumatic compression. However, clinical data supporting this, is as yet lacking.

Treatment of venous thrombosis in patients with cirrhosis, using routine anticoagulation with (low molecular weight) heparin and vitamin K antagonists, has been described, but an unacceptably high level of bleeding complications (83%) has been reported in one study [73]. A disadvantage of the use of heparin in patients with cirrhosis is the unpredictable efficacy, since heparin requires antithrombin to exert its anticoagulant effect, and antithrombin levels are frequently decreased in these patients. Also, the administration of vitamin K antagonists is difficult, since the INR of the PT is frequently prolonged in patients with cirrhosis, and it is thus unclear which target INR is safe. Furthermore, INR determinations in patients with liver disease suffer from unacceptably high inter-laboratory variation [119,120]. The new direct factor Xa and thrombin inhibitors have theoretical advantages over heparin and vitamin K antagonists, but for these agents suitable antidotes are still lacking. Moreover, several of these new agents are metabolized by the liver, which may also complicate the application in patients with cirrhosis. There is clearly a need for clinical studies

Meeting report

on optimal thromboprophylactic strategies in patients with liver disease.

Portal vein thrombosis

Data on treatment of PVT in patients with cirrhosis is scarce [81]. In one study, treatment with low molecular weight heparin followed by vitamin K antagonists with a target INR of 2–3 in patients listed for liver transplantation with a mean INR of 1.5 resulted in recanalization in 8 of 19 patients, whereas none of the 10 patients that did not receive anticoagulation showed thrombus resolution [82]. Based on the limited data available the recent American Association for the Study of Liver Disease (AASLD) guidelines stated that no recommendations for or against the use of anticoagulation in cirrhotic patients with PVT can be made at present. Future controlled clinical studies should investigate the safety and efficacy of anticoagulation in patients with PVT listed for transplantation with the aim of achieving recanalization or prevention of thrombus extension. Furthermore, patients with Child A cirrhosis, PVT, and established thrombophilia (e.g. carriers of the prothrombin 20210A mutation) have been suggested to benefit from anticoagulation, but again verification in clinical trials is required [121].

Hepatic artery thrombosis following liver transplantation

Early detection or prevention of HAT after liver transplantation is of utmost importance as the prognosis of patients with HAT is poor [122,123]. Because the activation of hemostasis may be involved [88,124], thromboprophylactic strategies may be of benefit although no randomized studies have been performed. However, one study retrospectively analyzed the effect of aspirin in patients with local risk factors for late hepatic artery thrombosis (due to vascular reconstructions). Patients who received aspirin had a substantially decreased risk of late hepatic artery thrombosis (3.6% vs. 0.6%, which is a relative risk reduction of 82%), suggesting that (excessive) platelet activation may be involved in the pathogenesis of this complication [125]. Although the use of more potent thromboprophylaxis is attractive to lower the risk of HAT, caution is warranted due to the precarious post-transplant hemostatic balance. However, in certain high-risk patients including complex vascular reconstructions and pediatric transplant recipients, the benefits may outweigh the risk. [126]. Efficacy and safety studies are needed.

Non-alcoholic fatty liver disease

The patient with NAFLD or NASH and thrombosis poses a particular clinical challenge. As the number of patients with NAFLD is expected to increase in the coming years, studies on how to deal with primary and secondary prevention of vascular disease in patients with NAFLD and NASH are urgently required. A particular challenge is the patient with NASH-cirrhosis and coronary disease who undergoes vascular stenting. Optimization of anticoagulant therapy to balance the risk will likely require sophisticated laboratory tests of thrombosis and platelet function but further study is needed to formulate specific recommendations. Potential problems with anticoagulation of the NAFLD/NASH patient include the effects of impaired liver function on agents metabolized in the liver and possibly the negative effects on renal function of aspirin and related drugs especially if portal hypertension is present. A potential beneficial side effect of anticoagulation is attenuation

of the progression of fibrosis by blunting parenchymal extinction and coagulation-mediated stellate cell activation [127].

Conclusions

Increasing clinical and laboratory data provide evidence for the concept of rebalanced hemostasis in patients with liver disease. The 'average' patient with liver disease has a relatively balanced, effective hemostatic system, preventing both thrombosis and bleeding. Conventional coagulation tests fail to capture this process. Consequently, routine efforts at correction of abnormal hemostatic parameters prior to invasive procedures are without a scientific basis and in fact may pose unwarranted risk with little or no benefit. Increasing experience with a restrictive transfusion policy in liver transplant surgery suggests that an on-demand transfusion strategy is safe and substantially reduces blood product use. This strategy not only reduces costs, but may also reduce transfusion-related complications. Although the 'average' patient is in a hemostatic balance, a proportion of patients will be off-balance and be at increased risk for either bleeding or thrombosis. Currently available laboratory tests cannot discriminate between these groups. Studies assessing the predictive value for bleeding or thrombosis using novel, more sophisticated laboratory tests will be required. Clearly, the optimal strategy for treatment and prevention of bleeding and thrombosis in the patient with liver disease is an area in need of extensive study to further question and change an old dogma which is without an evidence base.

Financial disclosure

None.

Key Points

- Routine diagnostic tests such as the prothrombin time (PT) and the platelet count do not adequately reflect the hemostatic status in patients with liver disease.
- Due to concomitant changes in both pro- and anti-hemostatic pathways, the average patient with liver disease is in hemostatic balance. This balance, however, is presumably less stable than in healthy individuals.
- Bleeding episodes frequently occur in patients with liver disease and may be related to dysregulated hemostasis, but these bleeding episodes cannot be predicted by routine diagnostic tests such as the PT.
- Although the prophylactic correction of abnormal hemostasis test results by blood product transfusion prior to invasive procedures to prevent bleeding is a commonly performed clinical practice, there is no scientific evidence for this, and this policy requires reconsideration.
- Strategies to treat bleeding complications in patients with liver disease require exploration in clinical studies.
- Thrombotic episodes can occur in patients with liver disease, despite profoundly abnormal routine hemostatic parameters (e.g., prolonged PT and/or thrombocytopenia).
- Optimal strategies for prevention and treatment of thrombosis in patients with liver disease should be explored in clinical studies.

Acknowledgements

We thank all members of the Coagulation in Liver Disease Study Group for their input: Drs. Q. Anstee, C. Berg, M. de Boer, P. Chowdary, Ph. de Groot, H. Janssen, F. Leebeek, M. Lesurtel, M. Levi, J. Levy, A. Sanyal, N. Shah, F. Violi, M. Vivarelli, P. Witters, J. de Wolf.

References

- [1] Lisman T, Leebeek FWG, de Groot PG. Haemostatic abnormalities in patients with liver disease. *J Hepatol* 2002;37:280–287.
- [2] Lisman T, Caldwell SH, Leebeek FW, Porte RJ. Is chronic liver disease associated with a bleeding diathesis? *J Thromb Haemost* 2006;4:2059–2060.
- [3] Tripodi A, Mannucci PM. Abnormalities of hemostasis in chronic liver disease: reappraisal of their clinical significance and need for clinical and laboratory research. *J Hepatol* 2007;46:727–733.
- [4] Northup PG, Sundaram V, Fallon MB, Reddy KR, Balogun RA, Sanyal AJ, et al. Hypercoagulation and thrombophilia in liver disease. *J Thromb Haemost* 2008;6:2–9.
- [5] Lisman T, Leebeek FW. Hemostatic alterations in liver disease: a review on pathophysiology, clinical consequences, and treatment. *Dig Surg* 2007;24:250–258.
- [6] Caldwell SH, Hoffman M, Lisman T, Macik BG, Northup PG, Reddy KR, et al. Coagulation disorders and hemostasis in liver disease: pathophysiology and critical assessment of current management. *Hepatology* 2006;44:1039–1046.
- [7] Lisman T, Bongers TN, Adelmeijer J, Janssen HL, de Maat MP, de Groot PG, et al. Elevated levels of von Willebrand factor in cirrhosis support platelet adhesion despite reduced functional capacity. *Hepatology* 2006;44:53–61.
- [8] Mannucci PM, Canciani MT, Forza I, Lussana F, Lattuada A, Rossi E. Changes in health and disease of the metalloprotease that cleaves von Willebrand factor. *Blood* 2001;98:2730–2735.
- [9] Reitsma S, Slaaf DW, Vink H, van Zandvoort MA, oude Egbrink MG. The endothelial glycocalyx: composition, functions, and visualization. *Pflügers Arch* 2007;454:345–359.
- [10] Senzolo M, Cholongitas E, Thalheimer U, Riddell A, Agarwal S, Mallett S, et al. Heparin-like effect in liver disease and liver transplantation. *Clin Liver Dis* 2009;13:43–53.
- [11] Tripodi A, Salerno F, Chantarangkul V, Clerici M, Cazzaniga M, Primignani M, et al. Evidence of normal thrombin generation in cirrhosis despite abnormal conventional coagulation tests. *Hepatology* 2005;41:553–558.
- [12] Tripodi A, Primignani M, Chantarangkul V, Dell'Era A, Clerici M, de Franchis R, et al. An imbalance of pro- vs. anti-coagulation factors in plasma from patients with cirrhosis. *Gastroenterology* 2009;137:2105–2111.
- [13] Lisman T, Bakhtiari K, Pereboom ITA, Hendriks HGD, Meijers J, Porte R. Normal to increased thrombin generation in patients undergoing liver transplantation despite prolonged conventional coagulation tests. *J Hepatol* 2010;52:355–361.
- [14] Lisman T, Leebeek FW, Mosnier LO, Bouma BN, Meijers JC, Janssen HL, et al. Thrombin-activatable fibrinolysis inhibitor deficiency in cirrhosis is not associated with increased plasma fibrinolysis. *Gastroenterology* 2001;121:131–139.
- [15] Argo CK, Caldwell SH. Epidemiology and natural history of non-alcoholic steatohepatitis. *Clin Liver Dis* 2009;13:511–531.
- [16] Targher G, Bertolini L, Scala L, Zoppini G, Zenari L, Falezza G. Non-alcoholic hepatic steatosis and its relation to increased plasma biomarkers of inflammation and endothelial dysfunction in non-diabetic men. Role of visceral adipose tissue. *Diabet Med* 2005;22:1354–1358.
- [17] Gigolini M, Targher G, Agostino G, Tonoli M, Muggeo M, De Sandre G. Liver steatosis and its relation to plasma haemostatic factors in apparently healthy men – role of the metabolic syndrome. *Thromb Haemost* 1996;76:69–73.
- [18] Villanova N, Moscatiello S, Ramilli S, Bugianesi E, Magalotti D, Vanni E, et al. Endothelial dysfunction and cardiovascular risk profile in nonalcoholic fatty liver disease. *Hepatology* 2005;42:473–480.
- [19] Natarajan A, Zaman AG, Marshall SM. Platelet hyperactivity in type 2 diabetes: role of antiplatelet agents. *Diab Vasc Dis Res* 2008;5:138–144.
- [20] Kopp CW, Kopp HP, Steiner S, Kriwanek S, Krzyzanowska K, Bartok A, et al. Weight loss reduces tissue factor in morbidly obese patients. *Obes Res* 2003;11:950–956.
- [21] Munoz SJ, Stravitz RT, Gabriel DA. Coagulopathy of acute liver failure. *Clin Liver Dis* 2009;13:95–107.
- [22] Kerr R, Newsome P, Germain L, Thomson E, Dawson P, Stirling D, et al. Effects of acute liver injury on blood coagulation. *J Thromb Haemost* 2003;1:754–759.
- [23] Pernambuco JR, Langley PG, Hughes RD, Izumi S, Williams R. Activation of the fibrinolytic system in patients with fulminant liver failure. *Hepatology* 1993;18:1350–1356.
- [24] Warnaar N, Lisman T, Porte RJ. The two tales of coagulation in liver transplantation. *Curr Opin Organ Transplant* 2008;13:298–303.
- [25] Lisman T, Caldwell SH, Leebeek FWG, Porte RJ. Hemostasis in chronic liver disease – Is chronic liver disease associated with a bleeding diathesis? *J Thromb Haemost* 2006;4:2059–2060.
- [26] Mannucci PM. Abnormal hemostasis tests and bleeding in chronic liver disease: are they related? No. *J Thromb Haemost* 2006;4:721–723.
- [27] de Boer MT, Molenaar IQ, Hendriks HG, Slooff MJ, Porte RJ. Minimizing blood loss in liver transplantation: progress through research and evolution of techniques. *Dig Surg* 2005;22:265–275.
- [28] Massicotte L, Beaulieu D, Thibeault L, Roy JD, Marleau D, Lapointe R, et al. Coagulation defects do not predict blood product requirements during liver transplantation. *Transplantation* 2008;85:956–962.
- [29] Massicotte L, Lenis S, Thibeault L, Sassiné MP, Seal RF, Roy A. Effect of low central venous pressure and phlebotomy on blood product transfusion requirements during liver transplantations. *Liver Transplant* 2006;12:117–123.
- [30] Castaneda B, Debernardi-Venon W, Bandi JC, Andreu V, Perez-Del-Pulgar S, Moitinho E, et al. The role of portal pressure in the severity of bleeding in portal hypertensive rats. *Hepatology* 2000;31:581–586.
- [31] Vieira da Rocha EC, D'Amico EA, Caldwell SH, Flores da Rocha TR, Silva Soares E, CS Dos, et al. A prospective study of conventional and expanded coagulation indices in predicting ulcer bleeding after variceal band ligation. *Clin Gastroenterol Hepatol* 2009;7:988–993.
- [32] Kamath PS, Lacerda M, Ahlquist DA, McKusick MA, Andrews JC, Nagorney DA. Gastric mucosal responses to intrahepatic portosystemic shunting in patients with cirrhosis. *Gastroenterology* 2000;118:905–911.
- [33] Segal JB, Dzik WH. Paucity of studies to support that abnormal coagulation test results predict bleeding in the setting of invasive procedures: an evidence-based review. *Transfusion* 2005;45:1413–1425.
- [34] Sharma M, Yong C, Majure D, Zellner C, Roberts JP, Bass NM, et al. Safety of cardiac catheterization in patients with end-stage liver disease awaiting liver transplantation. *Am J Cardiol* 2009;103:742–746.
- [35] De Gottardi A, Thevenot T, Spahr L, Morard I, Bresson-Hadni S, Torres F, et al. Risk of complications after abdominal paracentesis in cirrhotic patients: a prospective study. *Clin Gastroenterol Hepatol* 2009;7:906–909.
- [36] Rockey DC, Caldwell SH, Goodman ZD, Nelson RC, Smith AD. Liver biopsy. *Hepatology* 2009;49:1017–1044.
- [37] Boks AL, Brommer EJ, Schalm SW, Van Vliet HH. Hemostasis and fibrinolysis in severe liver failure and their relation to hemorrhage. *Hepatology* 1986;6:79–86.
- [38] Anantharaju A, Mehta K, Mindikoglu AL, Van Thiel DH. Use of activated recombinant human factor VII (rhFVIIa) for colonic polypectomies in patients with cirrhosis and coagulopathy. *Dig Dis Sci* 2003;48:1414–1424.
- [39] Park DH, Kim MH, Lee SK, Lee SS, Choi JS, Song MH, et al. Endoscopic sphincterotomy vs. endoscopic papillary balloon dilation for choledocholithiasis in patients with liver cirrhosis and coagulopathy. *Gastrointest Endosc* 2004;60:180–185.
- [40] Sindet-Pedersen S. Haemostasis in oral surgery – the possible pathogenetic implications of oral fibrinolysis on bleeding. Experimental and clinical studies of the haemostatic balance in the oral cavity, with particular reference to patients with acquired and congenital defects of the coagulation system. *Dan Med Bull* 1991;38:427–443.
- [41] Auzinger G, O'Callaghan GP, Bernal W, Sizer E, Wendon JA. Percutaneous trancheostomy in patients with severe liver disease and a high incidence of refractory coagulopathy: a prospective trial. *Crit Care* 2007;11:R110.
- [42] Agarwal B, Shaw S, Hari MS, Burroughs AK, Davenport A. Continuous renal replacement therapy (CRRT) in patients with liver disease: is circuit life different? *J Hepatol* 2009;51:504–509.
- [43] Argo CK, Balogun RA. Blood products, volume control, and renal support in the coagulopathy of liver disease. *Clin Liver Dis* 2009;13:73–85.
- [44] Gronbaek H, Johnsen SP, Jepsen P, Gislum M, Vilstrup H, Liver Tage-Jensen U, et al. BMC Gastroenterol 2008;8:16.
- [45] Stravitz RT, Kramer AH, Davern T, Shaikh AO, Caldwell SH, Mehta RL, et al. Intensive care of patients with acute liver failure: recommendations of the U.S. Acute Liver Failure Study Group. *Crit Care Med* 2007;35:2498–2508.
- [46] Sharara AI, Rockey DC. Gastroesophageal variceal hemorrhage. *N Engl J Med* 2001;345:669–681.

Meeting report

- [47] Violi F, Leo R, Basili S, Ferro D, Cordova C, Balsano F. Association between prolonged bleeding time and gastrointestinal hemorrhage in 102 patients with liver cirrhosis: results of a retrospective study. *Haematologica* 1994;79:61–65.
- [48] Violi F, Ferro D, Basili S, Quintarelli C, Saliola M, Alessandri C, et al. Hyperfibrinolysis increases the risk of gastrointestinal hemorrhage in patients with advanced cirrhosis. *Hepatology* 1992;15:672–676.
- [49] Tacke F, Fiedler K, Trautwein C. A simple clinical score predicts high risk for upper gastrointestinal hemorrhages from varices in patients with chronic liver disease. *Scand J Gastroenterol* 2007;42:374–382.
- [50] Siringo S, McCormick PA, Mistry P, Kaye G, McIntyre N, Burroughs AK. Prognostic significance of the white nipple sign in variceal bleeding. *Gastrointest Endosc* 1991;37:51–55.
- [51] Morales J, Moitinho E, Abalde JG, Fernandez M, Bosch J. Effects of the V1a vasopressin agonist F-180 on portal hypertension-related bleeding in portal hypertensive rats. *Hepatology* 2003;38:1378–1383.
- [52] Castaneda B, Morales J, Lionetti R, Moitinho E, Andreu V, Perez-Del-Pulgar S, et al. Effects of blood volume restitution following a portal hypertensive-related bleeding in anesthetized cirrhotic rats. *Hepatology* 2001;33:821–825.
- [53] Colomo A, Hernandez-Gea V, Madoz P, Carles A, Alvarez-Urturi C, Poca M, et al. Hymodynamic changes and transfusion strategies in cirrhotic patients with acute variceal bleeding. *Hepatology* 2009;50:403Aa.
- [54] Boyer JL, Chatterjee C, Iber FL, Basu AK. Effect of plasma-volume expansion on portal hypertension. *N Engl J Med* 1966;275:750–755.
- [55] Pereboom ITA, de Boer MT, Haagsma EB, Hendriks HGD, Lisman T, Porte RJ. Platelet transfusion during liver transplantation is associated with increased postoperative mortality due to acute lung injury. *Anesth Analg* 2009;108:1083–1091.
- [56] de Boer MT, Christensen MC, Asmussen M, van der Hilst CS, Hendriks HG, Slooff MJ, et al. The impact of intraoperative transfusion of platelets and red blood cells on survival after liver transplantation. *Anesth Analg* 2008;106:32–44.
- [57] Alter HJ, Klein HG. The hazards of blood transfusion in historical perspective. *Blood* 2008;112:2617–2626.
- [58] Shah NL, Caldwell SH, Berg CL. The role of anti-fibrinolytics, rFVIIa and other pro-coagulants: prophylactic versus rescue? *Clin Liver Dis* 2009;13:87–93.
- [59] Gazzard BG, Henderson JM, Williams R. Early changes in coagulation following a paracetamol overdose and a controlled trial of fresh frozen plasma therapy. *Gut* 1975;16:617–620.
- [60] Munoz SJ, Rajender Reddy K, Lee W. The coagulopathy of acute liver failure and implications for intracranial pressure monitoring. *Neurocrit Care* 2008;9:103–107.
- [61] Borzio M, Salerno F, Piantoni L, Cazzaniga M, Angeli P, Bissoli F, et al. Bacterial infection in patients with advanced cirrhosis: a multicentre prospective study. *Dig Liver Dis* 2001;33:41–48.
- [62] Goulis J, Armonis A, Patch D, Sabin C, Greenslade L, Burroughs AK. Bacterial infection is independently associated with failure to control bleeding in cirrhotic patients with gastrointestinal hemorrhage. *Hepatology* 1998;27:1207–1212.
- [63] Vivas S, Rodriguez M, Palacio MA, Linares A, Alonso JL, Rodrigo L. Presence of bacterial infection in bleeding cirrhotic patients is independently associated with early mortality and failure to control bleeding. *Dig Dis Sci* 2001;46:2752–2757.
- [64] Chau TN, Chan YW, Patch D, Tokunaga S, Greenslade L, Burroughs AK. Thrombelastographic changes and early rebleeding in cirrhotic patients with variceal bleeding. *Gut* 1998;43:267–271.
- [65] Montalto P, Vlachogiannakos J, Cox DJ, Pastacaldi S, Patch D, Burroughs AK. Bacterial infection in cirrhosis impairs coagulation by a heparin effect: a prospective study. *J Hepatol* 2002;37:463–470.
- [66] Senzolo M, Coppell J, Cholongitas E, Riddell A, Triantos CK, Perry D, et al. The effects of glycosaminoglycans on coagulation: a thromboelastographic study. *Blood Coagul Fibrinolysis* 2007;18:227–236.
- [67] Jun CH, Park CH, Lee WS, Joo YE, Kim HS, Choi SK, et al. Antibiotic prophylaxis using third generation cephalosporins can reduce the risk of early rebleeding in the first acute gastroesophageal variceal hemorrhage: a prospective randomized study. *J Korean Med Sci* 2006;21:883–890.
- [68] Hou MC, Lin HC, Liu TT, Kuo BI, Lee FY, Chang FY, et al. Antibiotic prophylaxis after endoscopic therapy prevents rebleeding in acute variceal hemorrhage: a randomized trial. *Hepatology* 2004;39:746–753.
- [69] Rasaratnam B, Kaye D, Jennings G, Dudley F, Chin-Dusting J. The effect of selective intestinal decontamination on the hyperdynamic circulatory state in cirrhosis. A randomized trial. *Ann Intern Med* 2003;139:186–193.
- [70] Gulley D, Teal E, Suvannasankha A, Chalasani N, Liangpunsakul S. Deep vein thrombosis and pulmonary embolism in cirrhosis patients. *Dig Dis Sci* 2008;53:3012–3017.
- [71] Sogaard KK, Horvath-Puho E, Gronbaek H, Jepsen P, Vilstrup H, Sorensen HT. Risk of venous thromboembolism in patients with liver disease: a nationwide population-based case-control study. *Am J Gastroenterol* 2009;104:96–101.
- [72] Northup PG, McMahon MM, Ruhl AP, Altschuler SE, Volk-Bednarz A, Caldwell SH, et al. Coagulopathy does not fully protect hospitalized cirrhosis patients from peripheral venous thromboembolism. *Am J Gastroenterol* 2006;101:1524–1528.
- [73] Garcia-Fuster MJ, Abdilla N, Fabia MJ, Fernandez C, Oliver V, Forner MJ. Venous thromboembolism and liver cirrhosis. *Rev Esp Enferm Dig* 2008;100:259–262.
- [74] Warnaar N, Molenaar IQ, Colquhoun SD, Slooff MJ, Sherwani S, de Wolf AM, et al. Intraoperative pulmonary embolism and intracardiac thrombosis complicating liver transplantation: a systematic review. *J Thromb Haemost* 2008;6:297–302.
- [75] Melato M, Mucli E, Poldrugo F, Valente M, Zanconati F, Okuda K. Stroke-cirrhosis relationship: an autopsy study in a heavy drinking population. *Ital J Gastroenterol* 1991;23:211–214.
- [76] Howell WL, MANION WC. The low incidence of myocardial infarction in patients with portal cirrhosis of the liver: A review of 639 cases of cirrhosis of the liver from 17, 731 autopsies. *Am Heart J* 1960;60:341–344.
- [77] Marchesini G, Ronchi M, Forlani G, Bugianesi E, Bianchi G, Fabbri A, et al. Cardiovascular disease in cirrhosis – a point-prevalence study in relation to glucose tolerance. *Am J Gastroenterol* 1999;94:655–662.
- [78] Britton KA, Gaziano JM, Sesso HD, Djousse L. Relation of alcohol consumption and coronary heart disease in hypertensive male physicians (from the Physicians' Health Study). *Am J Cardiol* 2009;104:932–935.
- [79] Rimm EB, Giovannucci EL, Willett WC, Colditz GA, Ascherio A, Rosner B, et al. Prospective study of alcohol consumption and risk of coronary disease in men. *Lancet* 1991;338:464–468.
- [80] Kadayifci A, Tan V, Ursell PC, Merriman RB, Bass NM. Clinical and pathologic risk factors for atherosclerosis in cirrhosis: a comparison between NASH-related cirrhosis and cirrhosis due to other aetiologies. *J Hepatol* 2008;49:595–599.
- [81] Tsochatzis EA, Senzolo M, Germani G, Gatt A, Burroughs AK. Systematic review: portal vein thrombosis in cirrhosis. *Aliment Pharmacol Ther* 2010;31:366–374.
- [82] Francoz C, Belghiti J, Vilgrain V, Sommacale D, Paradis V, Condat B, et al. Splanchnic vein thrombosis in candidates for liver transplantation: usefulness of screening and anticoagulation. *Gut* 2005;54:691–697.
- [83] Zocco MA, Di Stasio E, De Cristofaro R, Novi M, Aiora ME, Ponziiani F, et al. Thrombotic risk factors in patients with liver cirrhosis: correlation with MELD scoring system and portal vein thrombosis development. *J Hepatol* 2009;51:682–689.
- [84] Nonami T, Yokoyama I, Iwatsuki S, Starzl TE. The incidence of portal vein thrombosis at liver transplantation. *Hepatology* 1992;16:1195–1198.
- [85] Orloff MJ, Orloff MS, Orloff SL, Girard B. Portal vein thrombosis in cirrhosis with variceal hemorrhage. *J Gastrointest Surg* 1997;1:123–130, [Discussion].
- [86] Amitrano L, Guardascione MA, Brancaccio V, Margaglione M, Manguso F, Iannaccone L, et al. Risk factors and clinical presentation of portal vein thrombosis in patients with liver cirrhosis. *J Hepatol* 2004;40:736–741.
- [87] Duffy JP, Hong JC, Farmer DG, Ghobrial RM, Yersiz H, Hiatt JR, et al. Vascular complications of orthotopic liver transplantation: experience in more than 4, 200 patients. *J Am Coll Surg* 2009;208:896–903.
- [88] Lisman T, Porte RJ. Hepatic artery thrombosis after liver transplantation: more than just a surgical complication? *Transplant Int* 2009;22:162–164.
- [89] Wanless IR, Wong F, Blendis LM, Greig P, Heathcote EJ, Levy G. Hepatic and portal vein thrombosis in cirrhosis: possible role in development of parenchymal extinction and portal hypertension. *Hepatology* 1995;21:1238–1247.
- [90] MacPhee PJ, Dindzans VJ, Fung LS, Levy GA. Acute and chronic changes in the microcirculation of the liver in inbred strains of mice following infection with mouse hepatitis virus type 3. *Hepatology* 1985;5:649–660.
- [91] Fiorucci S, Antonelli E, Distrutti E, Severino B, Fiorentina R, Baldoni M, et al. PAR1 antagonism protects against experimental liver fibrosis. Role of proteinase receptors in stellate cell activation. *Hepatology* 2004;39:365–375.
- [92] Scotton CJ, Krupiczkoj MA, Konigshoff M, Mercer PF, Lee YC, Kaminski N, et al. Increased local expression of coagulation factor X contributes to the fibrotic response in human and murine lung injury. *J Clin Invest* 2009;119:2550–2563.

- [93] Calvaruso V, Maimone S, Gatt A, Tuddenham E, Thursz M, Pinzani M, et al. Coagulation and fibrosis in chronic liver disease. *Gut* 2008;57:1722–1727.
- [94] Anstee QM, Goldin RD, Wright M, Martinelli A, Cox R, Thursz MR. Coagulation status modulates murine hepatic fibrogenesis: implications for the development of novel therapies. *J Thromb Haemost* 2008;6:1336–1343.
- [95] Wright M, Goldin R, Hellier S, Knapp S, Frodsham A, Hennig B, et al. Factor V Leiden polymorphism and the rate of fibrosis development in chronic hepatitis C virus infection. *Gut* 2003;52:1206–1210.
- [96] Abe W, Ikejima K, Lang T, Okumura K, Enomoto N, Kitamura T, et al. Low molecular weight heparin prevents hepatic fibrogenesis caused by carbon tetrachloride in the rat. *J Hepatol* 2007;46:286–294.
- [97] Anfossi G, Russo I, Massucco P, Mattiello L, Doronzo G, De Salve A, et al. Impaired synthesis and action of antiaggregating cyclic nucleotides in platelets from obese subjects: possible role in platelet hyperactivation in obesity. *Eur J Clin Invest* 2004;34:482–489.
- [98] Papatheodoridis GV, Chrysanthos N, Cholongitas E, Pavlou E, Apergis G, Tiniakos DG, et al. Thrombotic risk factors and liver histologic lesions in non-alcoholic fatty liver disease. *J Hepatol* 2009;51:931–938.
- [99] Sullivan CM, Hickman IJ, Flight S, Campbell C, Crawford DH, Masci PP, et al. Altered clot kinetics in patients with non-alcoholic fatty liver disease. *Ann Hepatol* 2009;8:331–338.
- [100] Westerkamp AC, Lisman T, Porte RJ. How to minimize blood loss during liver surgery in patients with cirrhosis. *HPB (Oxford)* 2009;11:453–458.
- [101] Tripodi A, Primignani M, Chantarangkul V, Clerici M, Dell'Era A, Fabris F, et al. Thrombin generation in patients with cirrhosis: the role of platelets. *Hepatology* 2006;44:440–445.
- [102] Youssef WI, Salazar F, Dasarathy S, Beddow T, Mullen KD. Role of fresh frozen plasma infusion in correction of coagulopathy of chronic liver disease: a dual phase study. *Am J Gastroenterol* 2003;98:1391–1394.
- [103] Bernstein DE, Jeffers L, Erhardtson E, Reddy KR, Glazer S, Squiban P, et al. Recombinant factor VIIa corrects prothrombin time in cirrhotic patients: a preliminary study. *Gastroenterology* 1997;113:1930–1937.
- [104] Lodge JP, Jonas S, Oussoultzoglou E, Malago M, Jayr C, Cherqui D, et al. Recombinant coagulation factor VIIa in major liver resection: a randomized, placebo-controlled, double-blind clinical trial. *Anesthesiology* 2005;102:269–275.
- [105] Lodge JP, Jonas S, Jones RM, Olausson M, Mir-Pallardo J, Soefelt S, et al. Efficacy and safety of repeated perioperative doses of recombinant factor VIIa in liver transplantation. *Liver Transplant* 2005;11:973–979.
- [106] Planinsic RM, van der MJ, Testa G, Grande L, Candela A, Porte RJ, et al. Safety and efficacy of a single bolus administration of recombinant factor VIIa in liver transplantation due to chronic liver disease. *Liver Transplant* 2005;11:895–900.
- [107] Bosch J, Thabut D, Albillos A, Carbonell N, Spicak J, Massard J, et al. Recombinant factor VIIa for variceal bleeding in patients with advanced cirrhosis: a randomized, controlled trial. *Hepatology* 2008;47:1604–1614.
- [108] O'Connell KA, Wood JJ, Wise RP, Lozier JN, Braun MM. Thromboembolic adverse events after use of recombinant human coagulation factor VIIa. *JAMA* 2006;295:293–298.
- [109] Agnelli G, Parise P, Levi M, Cosmi B, Nenci GG. Effects of desmopressin on hemostasis in patients with liver cirrhosis. *Haemostasis* 1995;25:241–247.
- [110] Burroughs AK, Matthews K, Qadiri M, Thomas N, Kernoff P, Tuddenham E, et al. Desmopressin and bleeding time in patients with cirrhosis. *Br Med J (Clin Res Ed)* 1985;291:1377–1381.
- [111] de Franchis R, Arcidiacono PG, Carpinelli L, Andreoni B, Cestari L, Brunati S, et al. Randomized controlled trial of desmopressin plus terlipressin vs. terlipressin alone for the treatment of acute variceal hemorrhage in cirrhotic patients: a multicenter, double-blind study. *New Italian Endoscopic Club. Hepatology* 1993;18:1102–1107.
- [112] Pivalizza EG, Warters RD, Gebhard R. Desmopressin before liver transplantation. *Can J Anaesth* 2003;50:748–749.
- [113] Wong AY, Irwin MG, Hui TW, Fung SK, Fan ST, Ma ES. Desmopressin does not decrease blood loss and transfusion requirements in patients undergoing hepatectomy. *Can J Anaesth* 2003;50:14–20.
- [114] Porte RJ, Molenaar IQ, Begliomini B, Groenland TH, Januszkiewicz A, Lindgren L, et al. Aprotinin and transfusion requirements in orthotopic liver transplantation: a multicentre randomised double-blind study. *EMSALT Study Group. Lancet* 2000;355:1303–1309.
- [115] Boylan JF, Klinck JR, Sandler AN, Arellano R, Greig PD, Nierenberg H, et al. Tranexamic acid reduces blood loss, transfusion requirements, and coagulation factor use in primary orthotopic liver transplantation. *Anesthesiology* 1996;85:1043–1048.
- [116] Kohler M. Thrombogenicity of prothrombin complex concentrates. *Thromb Res* 1999;95:S13–S17.
- [117] McHutchison JG, Dusheiko G, Shiffman ML, Rodriguez-Torres M, Sigal S, Bourliere M, et al. Eltrombopag for thrombocytopenia in patients with cirrhosis associated with hepatitis C. *N Engl J Med* 2007;357:2227–2236.
- [118] Senzolo M, Sartori MT, Lisman T. Should we give thromboprophylaxis to patients with liver cirrhosis and coagulopathy? *HPB (Oxford)* 2009;11:459–464.
- [119] Trotter JF, Olson J, Lefkowitz J, Smith AD, Arjal R, Kenison J. Changes in international normalized ratio (INR) and model for endstage liver disease (MELD) based on selection of clinical laboratory. *Am J Transplant* 2007;7:1624–1628.
- [120] Lisman T, van Leeuwen Y, Adelmeijer J, Pereboom IT, Haagsma EB, van den Berg AP, et al. Interlaboratory variability in assessment of the model of end-stage liver disease score. *Liver Int* 2008;28:1344–1351.
- [121] Valla DC. Thrombosis and anticoagulation in liver disease. *Hepatology* 2008;47:1384–1393.
- [122] Bekker J, Ploem S, de Jong KP. Early hepatic artery thrombosis after liver transplantation: a systematic review of the incidence, outcome and risk factors. *Am J Transplant* 2009;9:746–757.
- [123] Gunsar F, Rolando N, Pastacaldi S, Patch D, Raimondo ML, Davidson B, et al. Late hepatic artery thrombosis after orthotopic liver transplantation. *Liver Transplant* 2003;9:605–611.
- [124] Lisman T, Porte RJ. Antiplatelet medication after liver transplantation: does it affect outcome? *Liver Transplant* 2007;13:644–646.
- [125] Vivarelli M, La BG, Cucchetti A, Lauro A, Del GM, Ravaioli M, et al. Can antiplatelet prophylaxis reduce the incidence of hepatic artery thrombosis after liver transplantation? *Liver Transplant* 2007;13:651–654.
- [126] Sieders E, Peeters PM, TenVergert EM, de Jong KP, Porte RJ, Zwaveling JH, et al. Early vascular complications after pediatric liver transplantation. *Liver Transplant* 2000;6:326–332.
- [127] Fujita K, Nozaki Y, Wada K, Yoneda M, Endo H, Takahashi H, et al. Effectiveness of antiplatelet drugs against experimental non-alcoholic fatty liver disease. *Gut* 2008;57:1583–1591.